

Segmentation of Retinal Nerve Fiber Layer in Optical Coherence Tomography (OCT) Images using Statistical Region Merging Technique for Glaucoma Screening

Chandrappa S.
SDM Institute of Technology
Ujire, Karnataka, India

Dharmanna Lamani
S. Jagadeesha, PhD
SDM Institute of Technology
Ujire, Karnataka, India

Ranjan Kumar H.S.
NMAM Institute of Technology
Nitte, Karnataka, India

ABSTRACT

The Retinal Nerve Fiber Layer thickness is one of the main clinical parameter used to diagnose glaucoma eye disease. The thickness of the RNFL decreases as the intraocular pressure inside the eye increases. Decrease in RNFL thickness or damages to RNFL due to high intraocular pressure leads to Glaucoma. The present work provides a technique for the segmentation of Retinal Nerve Fiber Layer (RNFL) from the Optical Coherence Tomography (OCT) images. First, OCT image is pre-processed then RNFL in OCT is segmented by statistical region merging algorithm. The segmented RNFL is refined using morphological operations such as dilation and erosion. At the end, segmented RNFL is extracted by developed algorithm. The developed technique is tested with 50 RNFL images. The result shows the exact boundaries of RNFL and segmented portion of the RNFL. Segmented RNFL can be used to find the thickness of RNFL for detection of glaucoma.

General Terms

Glaucoma, intraocular pressure (IOP)

Keywords

Optical coherence tomography (OCT), Retinal Nerve Fiber Layer (RNFL), RNFL Thickness

1. INTRODUCTION

Optical coherence tomography (OCT) is an instrument used to capture the high resolution, 3-dimensional images of the structural composition of biological tissue [7, 8]. These high resolutions, 3-dimensional images are called OCT images. It uses light waves to take pictures. OCT images obtained by scanning the eye are called OCT Eye images. One of the most important uses of OCT Eye images in ophthalmology field is retinal diseases detection [9]. Morphological features such as the thickness of retinal fiber nerve layer, the shape, macular holes, and blood vessels are used in retinal disease diagnostics. These morphological features are extracted and analyzed from OCT Eye images. For example, retinal nerve fiber layer (RNFL) thickness is the main parameter for diagnosis of glaucoma [10]. Glaucoma is a human eye disease. The main cause of glaucoma is loss of retinal nerve fibers due to increased pressure inside the eye known as intraocular pressure (IOP), as shown in Figure 1 [12]. This leads to the decrease in RNFL thickness. Therefore the estimation of RNFL thickness plays a major role in the analysis of glaucoma [11]. This paper presents the segmentation of RNFL from OCT Eye images. Segmented RNFL can be used to estimate the RNFL thickness for glaucoma detection.

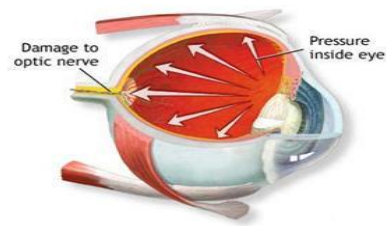


Fig. 1 Process of retina affected by glaucoma

2. RELATED WORK

Authors [1] presented the measurement of RNFL thickness and segmentation of RNFL using OCT images for glaucoma detection. In this work, both normal and abnormal images are taken for analysis. At first, pre-processing is done by median filter, in order to remove the speckle noise present in the OCT image. It is then followed by texture segmentation using Gabor filter for extracting all the layers in the image. Then the developed algorithm is used for RNFL segmentation leading to thickness measurement.

In this paper [2], Authors presented the intra-retinal layer segmentation in OCT images. Here, the individual layers are identified and segmented by means of two step kernel based optimization scheme. This proposed method, is used to process and segment the OCT images with low contrast, speckle noise and irregular shape structural features. Authors [3] presented the variational approach to automatic segmentation of RNFL on OCT data set of the retina. Here, the OCT data set is modeled as two probability density functions and the difference between these are described by symmetrized Kullback-Leibler distance. Then the level set method is used to segment the RNFL with high degree of accuracy.

This paper [4] presented segmentation of retinal nerve fiber layer from OCT images by using entropy method. The segmented RNFL is later smoothed by using Bezier curve technique.

Authors [5] were developed a new approach for segmentation of retinal nerve fiber layer from FD-OCT images. Here, the developed method is based on the minimization of an energy function consisting of gradient and local smoothing terms. Cabrera Fernández D et al [6], developed the novel method for segmentation of RNFL from OCT images. In this work, OCT images are processed using texture analysis by means of the structure tensor combined with complex diffusion filtering. Here, they were used STRATUSOCTTM system for segmentation of the various cellular layers of the retina in human eye

3. PROPOSED SYSTEM

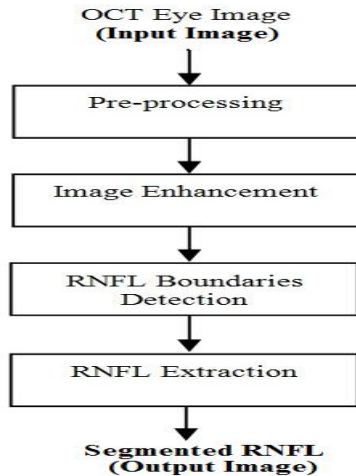


Fig. 2 Flow diagram of segmentation of RNFL

The process involved in segmentation of RNFL is schematically represented in Figure 2.

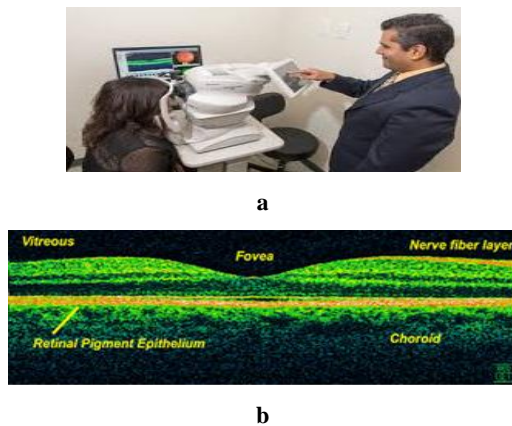


Fig. 3 a) OCT Device b) Structure of OCT Eye image

Figure 3 (a) shows coherence tomography device, which is used to capture human Eye images and (b) shows the interpretation of OCT eye image and different layers present in it [13]. The topmost layer of OCT Eye image is Retinal nerve fiber layer. In this work, proposed method extracts the topmost layer (i.e. RNFL layer) for glaucoma screening. One of the most common noises found in OCT images is speckle noise. This noise usually degrades segmentation process and decreases image quality. This leads to difficulties in image segmentation. To achieve the accurate segmentation, first the speckle noise should be eliminated. Therefore in the first stage, RGB OCT Eye image is processed using median filter in order to eliminate the speckle noise and other noises present in input image. Here, median filter is used for noise removal because of its edge preservation properties. In the Second stage, image enhancement technique is used to enhance a given image so that the result obtained from image enhancement is more useful than the original image for RNFL boundaries detection. Image enhancement sharpens image features such as edges, boundaries, or contrast to make an image more useful for further processing. The image adjustment function of MatLab is used to enhance the image. Image adjustment method is usually increasing the intensity of images. Through this image adjustment, the intensities can be better distributed on the histogram. This converts areas of

lower local contrast to higher contrast. This is accomplished by effectively spreading out the most frequent intensity values. Third stage is RNFL boundaries detection. Here Canny, Sobel and Prewitt edge detection algorithms were used to find the RNFL edges and these techniques were not provided significant results. Therefore line detection approach based on statistical region merging is used to detect boundaries of the RNFL. This algorithm grouping the similar pixels into one group and replace the each pixel of the group with average value of all pixels present in that group. Suppose consider 10 pixel values 1.2, 1.3, 1.4, 1.5, 7.2, 7.1, 7.4, 7.5, 7.5, 1.6. Algorithm groups these pixels into two groups. First group includes pixels values 1.2, 1.3, 1.4, 1.5, 1.6, and second group includes pixels values 7.2, 7.1, 7.4, 7.5, 7.5. Statistical region merging algorithm replaces the each pixel of the group by average value of all pixels of group (i.e. 1.4). In same way second group pixels are replaced with 7.34. Finally, output of this stage is binary image that includes boundaries of RNFL.

At the end, an algorithm is implemented for segmentation of RNFL from binary OCT image after detection of boundaries of RNFL. The RNFL is the first layer in OCT image, therefore implemented algorithm process OCT image from top to bottom. If it finds white pixels or white line that indicates upper layer of RNFL and the process continues until another white line is detected. Once the algorithm finds the second white line that indicates lower layer of RNFL then the algorithm will stop the processing of OCT image. This results in segmented RNF layer.

4. RESULT

4.1 Image Pre-processing

Figure 4 shows the image preprocessing. This phase takes the original OCT image, generates the red channel image consisting only red components presents in original OCT image, green channel image consisting the only green components presents in original OCT image and blue channel image consisting only blue components presents in original OCT image. Later de-noised image is obtained by applying the median filter algorithm to red, green and blue channel images and combining red, green and blue channel images.

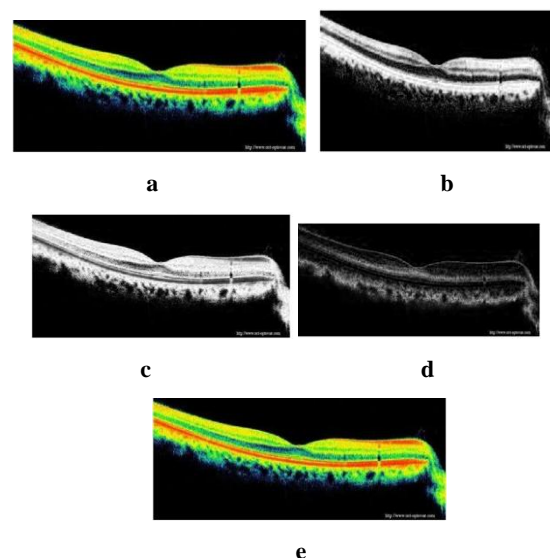


Fig. 4 Image pre-processing a) original OCT Eye image b) red channel image c) green channel image d) blue channel image e) de-noised image after pre-processing.

4.2 Image Enhancement

Figure 5 shows the image enhancement. This phase takes de-noised color OCT image generated by pre-processing phase and converts it into enhanced OCT image using image adjustment method.

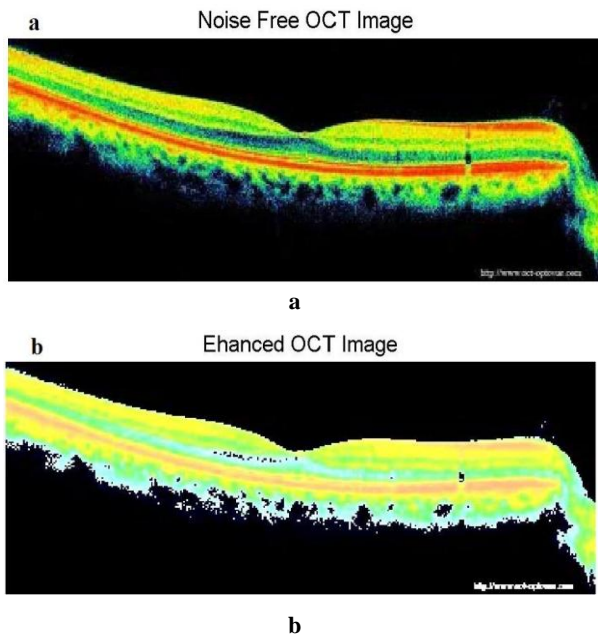


Fig. 5 Image enhancement a) Original OCT image b) Enhanced OCT image.

4.3 RNF Layer Edges Detection

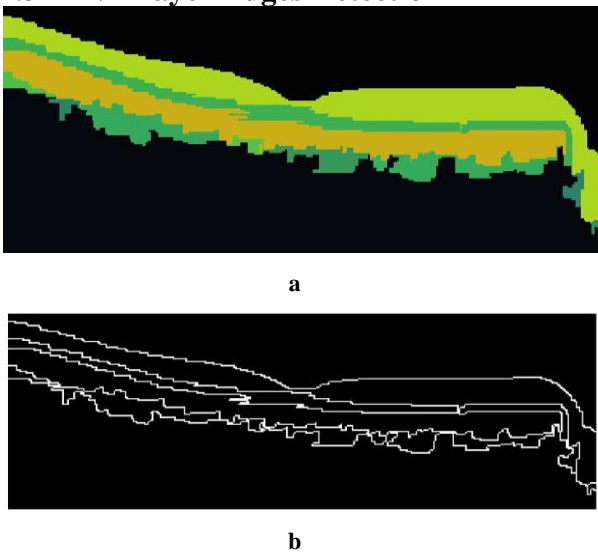


Fig. 6 (a) different layers of OCT and (b) Edges of RNFL layer

Figure 6 (a) shows the different regions of OCT image identified by statistical region merging algorithm. Figure 6 (b) shows RNFL layer boundaries detected from Enhanced OCT image. Here, boundaries of retinal nerve fiber layer are detected by statistical region merging algorithm.

4.4 RNFL Extraction

Figure 7 shows extracted RNFL layer from binary image after converting grayscale image into binary image. Here, grayscale image produced at the third phase is used to extract the retinal nerve fiber layer. First, grayscale image is

converted into binary image. Later, this binary image is used to extract RNFL using implemented algorithm.



Fig. 7 Extracted RNFL layer

5. CONCLUSION

In this paper, a novel approach for segmenting retinal nerve fiber layer in retinal OCT image is proposed. At first, pre-processing is done by median filter in order to remove the speckle noise present in the OCT image. It is then followed by image enhancement by using image adjustment to increase the brightness of image. It is then followed by RNFL boundary detection using Statistical region merging algorithm for extracting RNF layers in the image. Finally, RNFL is extracted by developed algorithm. The developed approach was demonstrated to achieve accurate retinal nerve fiber layer segmentation on retinal OCT images under low image contrast. The proposed approach shows higher potential for estimation of retinal layer thickness. Results of our proposed approach proved that RNFL extraction is concurrent with the ophthalmologist's opinion. In the future work, green, blue and green and blue channel images are considering for extraction of the RNFL region and also implementing novel method for RNFL thickness calculation using extracted RNFL. Also comparing our proposed approach efficiency with other approaches like Dijkstra's algorithm, gradient vector flow (GVF), Chan-Vese segmentation algorithm.

6. REFERENCES

- [1] Dhivyabharathi et al., "measurement of rnfl thickness using oct images for glaucoma detection", *ictact journal on image and video processing*, august 2013, volume: 04, issue: 01.
- [2] Akshaya Mishra et al., "Intra-Retinal Layer Segmentation in Optical Coherence Tomography Images", *Optics Express*, Vol. 17, No. 26, pp. 23719 - 23728, 2009.
- [3] Lu Zongqing et al., "A Variational Approach to Automatic Segmentation of RNFL on OCT Data Sets of the Retina", *IEEE International Conference on Image Processing*, pp. 3345 - 3348, 2009.
- [4] Ganesh Babu T R et al., "retinal nerve fiber layer segmentation of oct images by entropy method", *Research Journal of Pharmaceutical, Biological and Chemical Sciences*, ISSN: 0975-8585, September October 2014.
- [5] Markus A. Mayer et al., "Retinal Nerve Fiber Layer Segmentation on FD-OCT Scans of Normal Subjects and Glaucoma Patients", *Biomed Opt Express*, doi: 10.1364/BOE.1.001358.
- [6] Cabrera Fernández D et al., "Automated detection of retinal layer structures on optical coherence tomography images", *Opt Express*. 2005 Dec 12;13(25):10200-16.
- [7] D. Huang, E. Swanson, C. Lin, J. Schuman, W. Stinson, W. Chang, M. Hee, T. Flotte, K. Gregory, C. Puliafito,

- and J. Fujimoto, "Optical coherence tomography," *Science* 254, 1178-1181 (1991).
- [8] A.F. Fercher, "Optical coherence tomography," *J. Biomed. Opt.* 1, 157-1996.
- [9] J. Fujimoto et al., "Optical Coherence Tomography (OCT) in ophthalmology: introduction," *Opt. Express* 17(5), 3978-3979 -2009.
- [10] C. Leung et al., "Evaluation of retinal nerve fiber layer progression in glaucoma with optical coherence tomography guided progression analysis", *Invest. Ophthalmol. Visual Sci.* 2009.
- [11] Mansoori T et al., "Reproducibility of peripapillary retinal nerve fiber layer thickness measurements with spectral domain optical coherence tomography in normal and glaucomatous eyes", *Br J Ophthalmol* 95: 685-688.
- [12] Online: http://www.thetechnologysource.biz/files/RNFL_Chapter1.pdf.
- [13] Online: <http://multiple-sclerosis-research.blogspot.com>.